



PATIENT

Riku Algarin

PRESENTING CLINICAL SIGNS

Dental calculus

SPECIES

Feline

Abnormal PE/Chem/CBC/UA Results: Heart murmur grade 2/6 BroBNP- positive Bw- wnl

BREED

DSH

ULTRASONOGRAPHIC EXAMINATION OF THE HEART

SEX

MN

AGE

7

WEIGHT

10.8

FELINE CARDIAC PARAMETERS	BODY WEIGHT (kg)	HR (BPM)	IVSd (cm)	LVIDd (cm)	LVWd (cm)	FS (%)	EF (%)
NORMAL PARAMETER	-----	150-240	0.3-0.6	1.0-2.1	0.25-0.6	35-67	80-100
PATIENT	--	NM	0.45	1.53	0.4	48	81
FELINE CARDIAC PARAMETERS	LA/AO M-Mode	LA/AO HEART BASE (Sisson)	LAD LA MAX 4 Chamber		LVOT VEL. (m/s)	RVOT VEL. (m/s)	IVRT (m/)
NORMAL PARAMETER	<1.5	1.6	0.7-1.7		<1.6	<1.3	40-60
PATIENT	--	1.4	1.3		1.0	0.95	NM

Cardiac Presentation

The echocardiogram in this patient demonstrated normal left atrial size based on 2 separate LA measurements. The cranial and caudal mitral valve leaflets presented normal linear structure and kinetics. No overt MR present on Doppler. The left ventricle presented normal thicknesses with linear contour and was not dilated nor restricted. The myocardium presented normal echogenicity without subjective evidence of significant fibrotic or ischemic disease. The contractility of the ventricular walls was adequate and in normal range for this patient evidenced by the fractional shortening measurement and subjective evaluation of the different regions and angles of the myocardium. The left ventricular outflow tract demonstrated normal laminar flow and subjective structural integrity. Normal measured LVOT velocity was present. The right atrium and auricle revealed normal size, structure and content. No evidence of masses was noted or chamber overload. Tricuspid valvular assessment demonstrated adequate linear morphology and kinetics. No overt TR present on Doppler. The right ventricle was of normal size (1/3 diameter of LV), chordae structure, myocardial echogenicity and thickness. Pulmonic tract assessment revealed normal valve structure, laminar flow, and diameter (approx.1:1 pa/ao ratio). Normal measured RVOT velocity was present. No visible pericardial or free pleura fluid was noted or extra cardiac pathology in the visible planes. The cranial mediastinum and pericardial regions were free of masses in the visible window.

ULTRASONOGRAPHIC FINDINGS

Primary

- Normal cardiac structure/function

INTERPRETED BY

R. McKenzie Daniel, DVM, DABVP (Canine and Feline)

IMAGING PERFORMED BY

Dr SHarkawy

HOSPITAL NAME

Kew Gardens Animal Hospital

REFERRING VET

Dr Elyas

INVOICE 23395

DATE 12-31-25



PATIENT

Riku Algarin

SPECIES

Feline

BREED

DSH

SEX

MN

AGE

7

WEIGHT

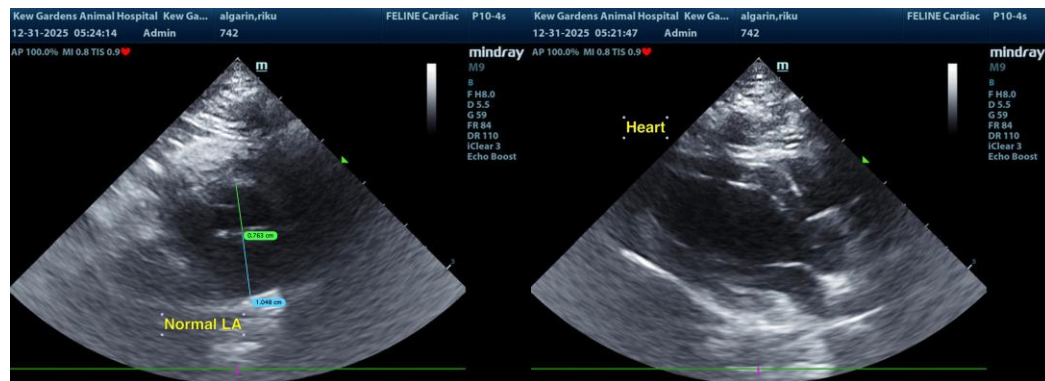
10.8

INTERPRETATION OF THE FINDINGS & FURTHER RECOMMENDATIONS

Assuming no volume changes such as dehydration or anemia, a benign flow murmur is probable, although a small non-visualized flow abnormality cannot be excluded. Regardless of classification, the hemodynamic effects of the murmur are low. No indication for cardiac medication.

Conservative monitoring of the low grade murmur going forward is advised. Recheck echo suggested in 6-12 months, sooner if increase in murmur intensity or if clinical signs arise.

Anesthetic risk is considered low. Suggested anesthetic protocol may include opioid or Benzodiazepine pre-med, induction with Propofol or Alfaxalone, and appropriate gas anesthesia with avoidance of alpha 2 agonists.



INTERPRETED BY

R. McKenzie Daniel,
DVM, DABVP
(Canine and Feline)

IMAGING PERFORMED BY

Dr SHarkawy

HOSPITAL NAME

Kew Gardens Animal
Hospital

REFERRING VET

Dr Elyas

INVOICE 23395

DATE 12-31-25

The information and recommendations provided are based on the images presented by the referring veterinarian/sonographer. No evaluation can be communicated regarding pathology that was not visible in the image/video clips provided.

Thank you for this referral. If the clinical or image interpretation does not parallel your findings or if I can be of any further assistance, please contact me.

R. McKenzie Daniel, DVM, DABVP (Canine/Feline Practice)
info@sonopath.com